

# Clinical Case of Effective Fetal Stem Cells Treatment in a Patient with Autism Spectrum Disorder

A.A. Sinelnik\*, S.G. Shmyh, I.G. Matiyashchuk, M.O. Klunnyk, M.P. Demchuk, O.O. Honza, I.S. Vynychuk, I.A. Susak, K.O. Kuzmak, M. S. Nahrebelna, M.V. Skalozub, D.V. Vatlitsov, A.V. Tkachenko and K.I. Sorochynska.

Cell Therapy Center EmCell, Kyiv, Ukraine.

\*Corresponding Author: A.A. Sinelnik, MD, Cell Therapy Center EmCell, 40A Metrolohichna Street, Kyiv 03143, Ukraine.

Received date: **September 03, 2025**; Accepted date: **September 10, 2025**; Published date: **September 16, 2025**

Citation: A.A. Sinelnik, S.G. Shmyh, I.G. Matiyashchuk, M.O. Klunnyk, M.P. Demchuk, et al, (2025), Clinical Case of Effective Fetal Stem Cells Treatment in a Patient with Autism Spectrum Disorder, *J Clinical Research and Reports*, 21(1); DOI:10.31579/2690-1919/568

Copyright: © 2025, A.A. Sinelnik. This is an open access article distributed under the Creative Commons Attribution License, which permits unrestricted use, distribution, and reproduction in any medium, provided the original work is properly cited.

## Abstract

There are certain limitations in modern pharmacotherapy and rehabilitation psychotherapy for children with autism spectrum disorders (ASD). Existing therapeutic approaches are not able to assure a complete cure for the patients with ASD. Stem cell therapy is one of the promising and innovative methods that has recently gained popularity. To objectively assess the treatment effectiveness in medicine, both standardized psychiatric diagnostic methods and the instrumental investigations have been efficiently used. The neuroimaging methods are among them, especially, functional magnetic resonance imaging (fMRI) and diffusion tensor MR imaging (DTI); electroencephalography (EEG) and evoked cognitive potentials; dynamic monitoring of the treatment results. All these methods allow objectively evaluating the effects of stem cell therapy. This case report describes a clinical case of successful treatment with application of fetal stem cells in a child with ASD, complicated by the cognitive epileptiform disintegration. The child's general condition and assessment of positive changes by the caregivers were monitored during a period of 12 months. During one year of child's observation, the family noticed significant improvements proved by the results of the ATEC questionnaire, EEG data and the fractional anisotropy (FA) results. The presented clinical case demonstrates the potential of fetal stem cell (FSC) therapy as an effective treatment method for children with ASD, which is also confirmed by the obtained objective results.

**Key Words:** autism spectrum disorder; cognitive epileptiform disintegration; evoked cognitive potentials; fractional anisotropy; diffusion tensor MR imaging; standardized psychiatric diagnostic methods

## Introduction

Autism spectrum disorder (ASD)! What do we know about this disease today? We would like to give some latest updates about this health problem. The scientists still don't know the exact causes of ASD. It is thought to be caused by a combination of some genetic and environmental factors [1]. According to the latest statistic report from the Center for Disease Control and Prevention (CDC), 1 in 31 of 8-year-old kids in the United States has been diagnosed with autism. The prevalence of autism in the United States has increased by 312% since 2000. In 2000, the CDC data estimated that autism affects 1 in 150 among the 8-year-olds, or 6.7 cases per 1,000 children. Since then, a new report has been published every two years and the prevalence rate of ASD has been increasing each time [2]. As recorded, around 26.7% of the 8-year-olds with autism in the United States have an advanced autism grade with their symptoms so severe that kids eventually might need a 24-hour care for the rest of their lives. Another study found that children with ASD are 40 times more likely to suffer fatal injuries if compared to their peers without autism [3,4]. About 50% of mothers of ASD kids demonstrated the symptoms of depression. According to a report issued in 2022, the researchers at the University of California, San Francisco observed the higher levels of depression symptoms in about half of all mothers of ASD children over the 18-months period of follow up. Meanwhile, the rates of depression

among the mothers of children without autism ranged from 6% to 13.6% [5]. A high comorbidity between epilepsy and ASD has been characteristic for up to 30% of autistic cases. Likely co-occurrence of both disorders is the result of some genetic and structural differences in the brain [6,7]. However, epilepsy is not the only condition associated with ASD. Gastrointestinal disorders are 8 times more common in children with ASD and 7 out of 10 patients diagnosed with ASD have problems with eating habits and feeding [1]. At present, there is an evidence suggesting that stem cell (SCs) therapy significantly improves the condition of ASD patients and does not cause serious side effects [8,9,10,11]. SCs can be split depending on their origin: embryonic SCs (including induced pluripotent SCs), fetal stem cells (FSCs) and adult SCs (from umbilical cord blood, placenta, bone marrow, immobilized blood, adipose tissue, etc.) [12,13]. We would like to share our clinical experience of dynamic observation for a child with ASD who received a single course of FSCs treatment and its effectiveness was confirmed by the Autism Treatment Evaluation Checklist (ATEC) questionnaire and the MRI - diffusion tensor MR imaging findings.

## Case presentation

The parents of a 12-year-old child visited EmCell clinic for SCs treatment. The patient's mother reported the following chief complaints: expressive language impairment, emotional and volitional disorders, the child cannot use his skills to communicate, the patient also has impaired writing (child can lose his writing skills which are gradually restored after that). The patient reveals poor reading and behaves aloof with the other children. The child has mood swings, with remarkable shyness and showing interest in imitating the behavior of the older boys. The mother noted that child has problems with body coordination at time of riding a bicycle, the patient has to wrap himself tightly in a blanket when trying to fall asleep. The patient's body weight at birth was 4000 g; and height was 55 cm. Apgar's range after birth made up 9-10 scores. The child received breastfeeding for up to the age of 9 months. According to mother, she noticed some neurodevelopmental problems in the child's age of 1.5 years. After a certain period of time, mother revealed a regression in child's speech skills, with remarkable "facial dolorosa" on the photo, and "acetone smell" which occasionally appeared too. In this regard, the patient was engaged into special correctional classes with a teacher. At the age of 4 years, as recorded from mother, the child was consulted by a psychiatrist and a firm diagnosis of autism was confirmed. Since his age of 6 years, the patient has been under the constant supervision by the

pediatric psychiatrist at the "Treatment and Diagnostic Center of Neurology and Epileptology" in Bila Tserkva Town, where the child's diagnosis was identified as follows: "Autism spectrum disorder. Delayed psychomotor development. Cognitive epileptiform disintegration". After establishing the diagnosis, the child has been regularly receiving trainings with a psychologist, pedagogical classes and speech therapy correction. Besides, Ospolot (Sultiam) drug 100 mg/day was prescribed. When family changed their residence place (moved to another country due to russia's military aggression against Ukraine), the mother noted regress of child's speech and communication; however, a year later, upon returning to Ukraine, positive child's dynamics appeared.

From the age of 9 years, child began attending a specialized educational institution. The patient's skills of writing and reading were gradually developing. At the age of 10 years, child had a consultation with a local psychiatrist and the treatment scheme was corrected: Depakine chrono-300 was prescribed ½ tab. 2 times a day for continuous administration, after which the mother reported some positive dynamics in child's communication skills. Subsequently, child's therapy with Depakine chrono had been taken as a life-long prescription. The child attends inclusive program at school; mother is the child's assistant at school (Figure 1).



**Figure 1:** Mother and child during the school classes.

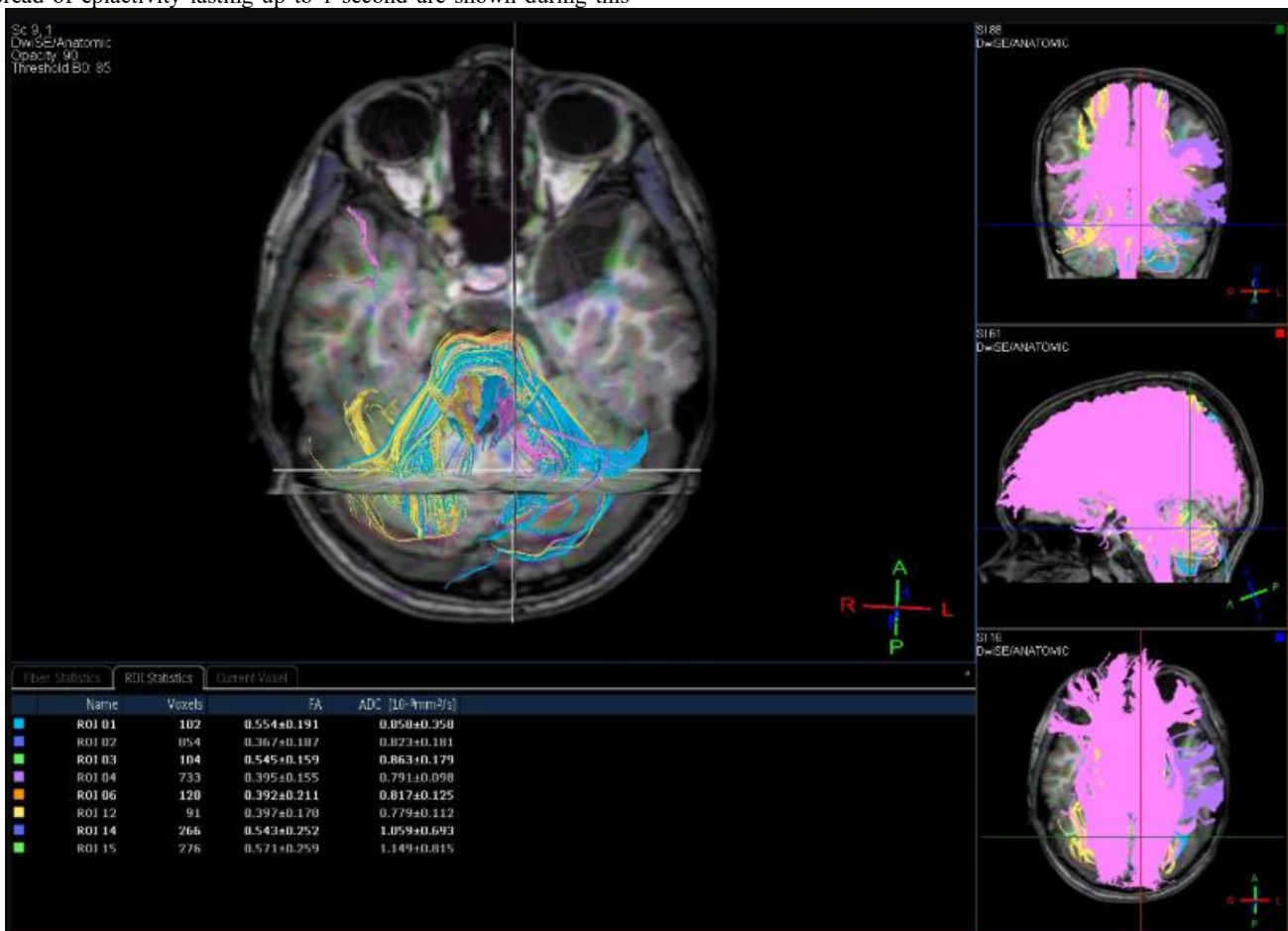**Examination results**

ASD was diagnosed in accordance with the diagnostic criteria due to the International Classification of Diseases, 10<sup>th</sup> revision (ICD-10) [14]. It involved the detection of speech development disorders (delayed receptive and expressive speech), including problems with social and functional interaction in a child under the age of three. The evaluation was carried out by means of the interviews with the parents to analyze autistic behavior by the ADI-R+ADOS assessment scale and the ATEC questionnaire application [15], the latter was also used to evaluate the effectiveness of ASD treatment. The results received by the ATEC assessment scale at the beginning of the study: language/communication level - 10 scores, socialization - 22 scores, sensory/cognitive skills - 12 scores, health/physical development/behavior - 21 scores. The child met the criteria for moderate childhood autism (65 scores).

EEG in awakening was performed before the treatment and demonstrated the sharp-wave elements in the following zones: right frontocentral, right central-parietal, with impulse conductivity to the left frontocentral and vertex zones. The single episodes of diffuse spread of epiactivity lasting up to 1 second are shown during this

investigation. The index of epileptiform activity is low/medium and the greatest presentation is during child's falling asleep. According to the results of MRI of the brain and diffusion tensor MR imaging before treatment (Philips Ingenia 3T magnetic resonance tomograph):

- 1) the architectonics of the corpus callosum associative fibers is unchanged, whereas the average FA values remain within the age norm - (FA) 0.413+/-0.207;
- 2) the arcuate fasciculus fibers between Wernicke's and Broca's areas are clearly visualized; their architectonics is not disrupted; the FA values are moderately reduced 0.397+/-0.179 (n=0.450+/-0.08), which may lead to impaired connectivity of expressive-receptive speech areas (impact on the child's ability to reproduce language sounds and perceive such sounds as linguistically significant);
- 3) the corticospinal tracts are relatively symmetrical and their architectonics is not affected, the average anisotropy indicators are without any deviations from the normal range: right - (FA) 0.454+/-0.199, left - (FA) 0.471+/-0.201.

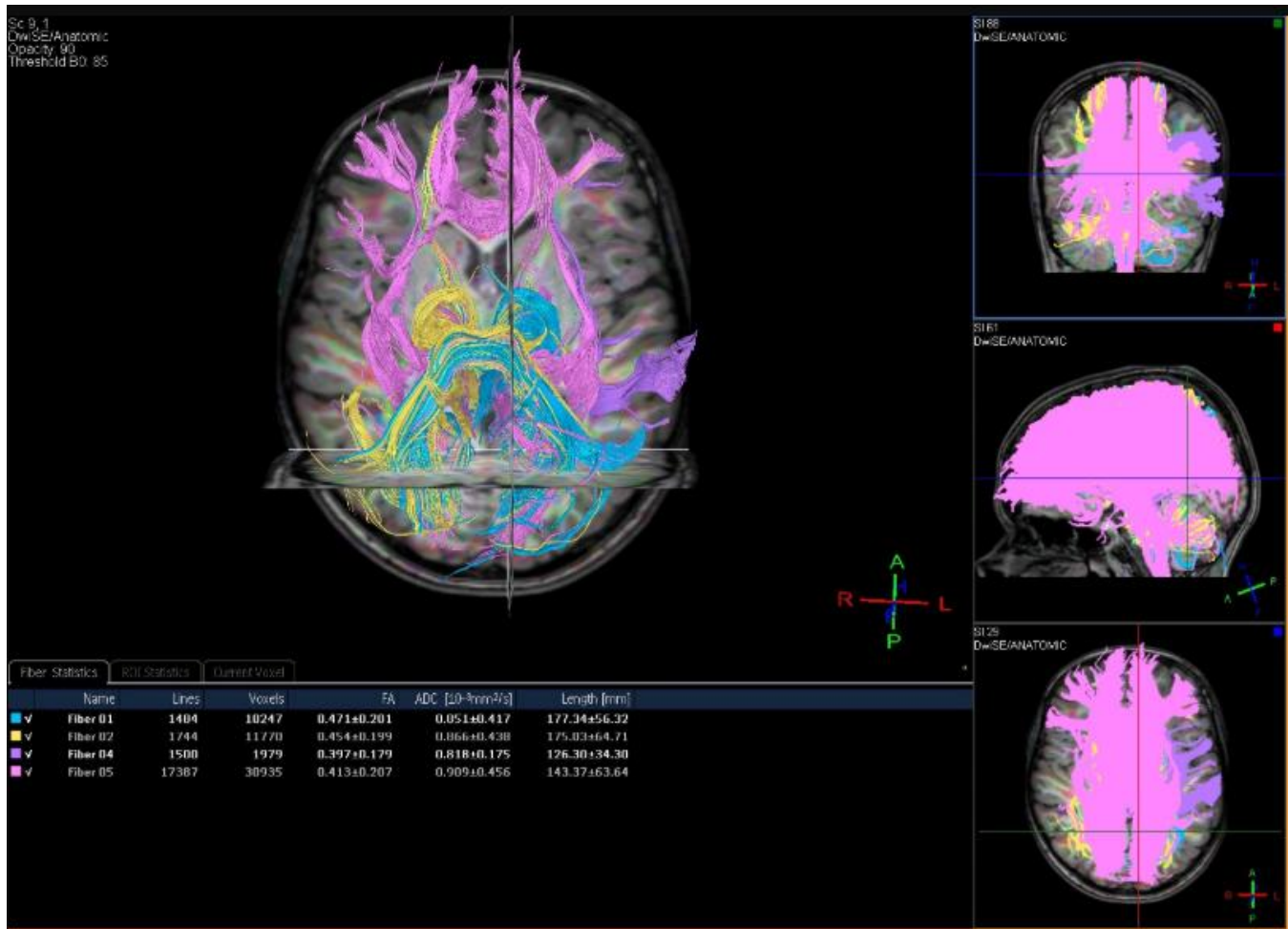

**Figure 2:** Diffusion tensor MR imaging findings before treatment.

**Conclusion**

MR signs of arachnoid cyst in the left temporal-polar zone (type I after Galassi). The changes at the level of the left hippocampus are corresponding to Incomplete Hippocampal Inversion (IHI). No volumetric-focal pathology in the brain was detected during the examination. A moderate decrease in the average FA does not exclude a "violation of connectivity" between Wernicke's and Broca's areas (impact on the child's ability to reproduce speech sounds and perceive them as

linguistically significant). The results of routine laboratory blood tests prior to treatment did not show any significant deviations from the reference values. The results of biochemical blood tests revealed a preliminarily increased level of alkaline phosphatase (286.6 U/l; RR 53-128 U/l) and total creatinine phosphokinase (198.4 mmol/l; RR <171 mmol/l). We would like to particularly emphasize that the levels of blood cyanocobalamin, folic acid, homocysteine, and blood immunogram were within the reference range.



**Figure 3:** Diffusion tensor MR imaging findings before treatment.

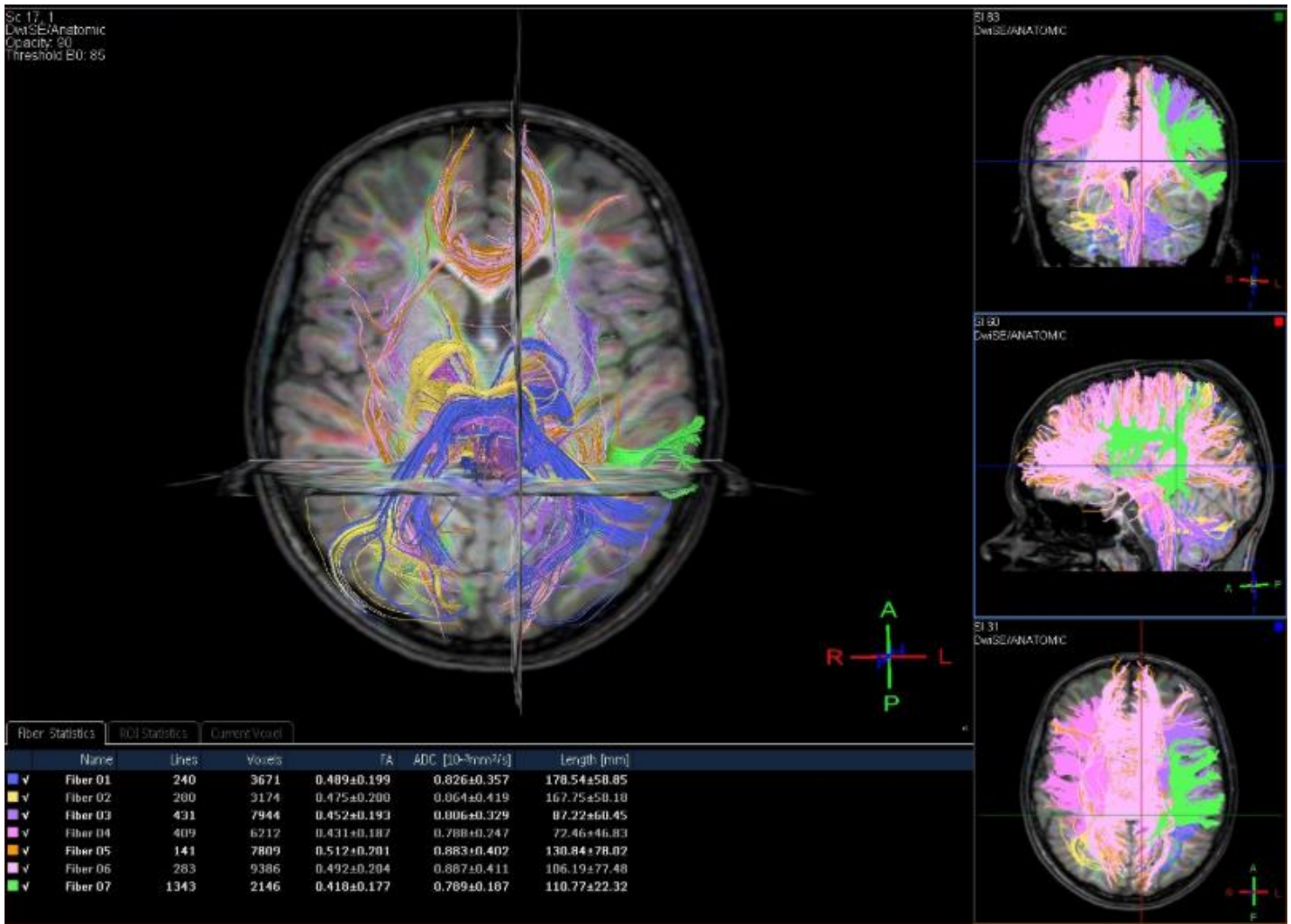
### Treatment

The patient received the course of FSCs therapy, hyperbaric oxygenation sessions (19.1 psi, 40 min, Fortius420® Hyperbaric Chamber) and training classes with an occupational therapist [16, 17, 18]. The SCs treatment protocol included intravenous administration of the fetal hemopoietic and mesenchymal SCs, subcutaneous and intranasal administration of neural SCs [11]. The child also received treatment with inhalation of exosomes isolated from the FSCs. No adverse reactions associated with SCs therapy were recorded during the treatment and within the whole period of observation [19].

### Examination post-treatment

During the doctor's examination over 6 months post-treatment, positive dynamic was noted in the form of improved perception of the addressed speech (ability to perform simple and complex instructions, no need for additional explanations or examples), improved child's ability to explain verbally. Partial inconsistency between the age and development of social dialogue language remained. No difficulties were reported with

understanding of logical and grammatical constructions, as well as establishing the cause-and-effect relationships. Understanding of the social and emotional context of situations was present, duration of child's concentration and ability to maintain attention improved. The patient's impulsivity changed from constant to sporadic. However, the child still has moderate deficit with ability to organize the educational process. After the course of SCs therapy, mother also noticed a number of positive changes in the child: the process of self-care following defecation improved, writing skills returned to the initial levels, patient's volume of processing for the information read and understanding of its contents was accelerated, child's preferences for watching television changed (patient prefers movies for kids, but previously child liked the animated cartoons). The patient tries to establish eye contact when it is necessary for communication and there is demonstration of satiety feelings when child consumed some foods. Mother also noted a positive behavioral and psycho-emotional background in the child. The patient's preferences in a style of clothing, haircut and behavior changed, which child could copy from the older boys.



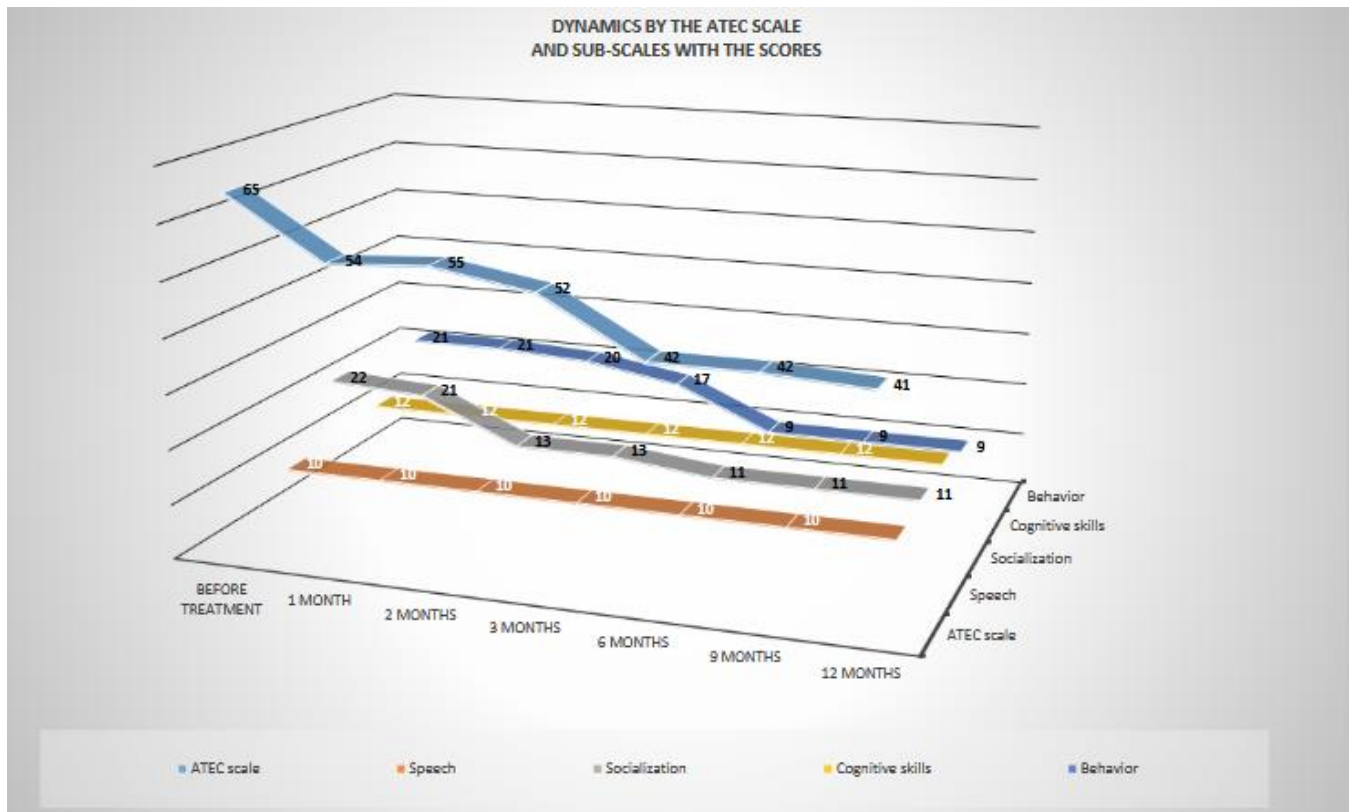
**Figure 4:** Diffusion tensor MR imaging findings after treatment.

The results of dynamic brain MRI investigation and diffusion tensor MR imaging (Philips Ingenia 3T magnetic resonance imaging) over 6 months after SCs therapy, compared with the data of the previous MR study, showed increasing of the average FA over the associative corpus callosum

fibers and arcuate fasciculus in Wernicke/Broca’s area, which may have a positive effect on the associative connectivity between the cerebral hemispheres and ability to reproduce speech sounds and perceive them as linguistically significant (Table 1).

Tract	Fractional anisotropy (FA) before treatment	Fractional anisotropy (FA) over 6 months after the treatment
Architectonics of the corpus callosum associative fibers	0.413+/-0.207	0.492 +/- 0.204
Arcuate fasciculus fibers between Wernicke and Broca's areas	0.397 +/- 0.179 (n- 0.450 +/- 0.08)	0.418+/-0.177
Right corticospinal tracts	0.454 +/- 0.199	0.475+/-0.200
Left corticospinal tracts	0.471+/-0.199	0.489 +/- 0.201

**Table 1:** Results of dynamic brain MRI investigation and diffusion tensor MR imaging



**Diagram 1:** Dynamics by the ATEC scale and sub-scales with the scores.

In accordance with the ATEC scale, the results showed a gradual decrease from 65 scores to 42 scores over the first 6 months and remained at that level over the next 6-month period of observation (42-41 scores).

It is worthy to emphasize that in isolation these changes affected the behavior and socialization sub-scales (Diag. 1).

The analysis of all data indicates a correlation between the results of MRI – diffusion tensor MR imaging, the scores by the ATEC questionnaire, and the reported mother’s subjective opinion.

According to the EEG results in dynamics: positive advantages have been identified in the form of decreasing the index and amplitude of epileptiform activity, the area of its distribution, and increasing alpha rhythm frequency.

## Discussion

The existing results of scientific studies indicate that SCs therapy does not cause any serious side effects. The use of SCs significantly improves the condition of the patients with ASD [8]. The SCs, as the tissue units of biological systems, are responsible for the regeneration and development of the organs, tissues – that is, they promote a self-renewal and differentiation into the cell lineages of different groups [9]. FSCs have a number of advantages making their clinical use the most effective method of SCs therapy, which is a promising factor for the treatment of ASD in kids. These SCs, derived from fetal tissues, possess higher potential for differentiation and capacity to self-renewal. FSCs induce an extensive differentiation potential compared to the adult SCs, as well as the lower chances of genetic and epigenetic mutations, a tendency to form tumors and immunogenicity compared to the pluripotent SCs [20]. FSCs developed ability to multiply rapidly and can differentiate into various cell types, which makes them valuable for effective clinical use. If we compare the embryonic SCs versus FSCs, fetal cells are less likely to induce an adverse immune reaction and do not lead to tumor formation. This case of the child who received treatment with FSCs deserves a particular attention. Positive results of clinical examinations are

confirmed by the objective instrumental data. The use of screening methods of examination and cognitive tests to identify ASD in children is regarded as universal, but not optimal tool for monitoring the treatment effectiveness. Genetic testing helps to identify certain genetic abnormalities that may be associated with the disease, but they are also not decisive for the diagnosis and assessment of the effectiveness of therapy.

Brain MRI and diffusion tensor MR imaging are ensured due to digitally processed diffusion tensor imaging (DTI) which is a modern brain imaging technique with application of a magnetic resonance imaging (MRI) to visualize the structures and connective links of the brain. Most of DTI studies in the patients with ASD demonstrate tract alterations, namely lower FA and/or higher values of the mean diffusivity (MD) over the distant anterior-posterior and interhemispheric fiber tracts [21]. For example, DTI studies have revealed abnormalities in associative tracts such as the superior longitudinal fasciculus, arcuate fasciculus, cingulum, and corpus callosum. Children with ASD have shown the altered FA, which is an evidence of atypical white matter microstructure. These changes have been correlated with the level of speech development among the patients [22,23]. Patients with ASD show a reduced structural-functional connectivity within the associative tracts such as the sagittal layer and internal capsule. Such advantages correlate with the severity of ASD symptoms, which eventually highlight the importance of a comprehensive approach to cerebral white matter investigations [24]. The clinical case that is presented above suggests a clear example of effective treatment of ASD, which is confirmed by the results of FA at the individual conductive pathways in the brain and the results of EEG monitoring. The rapid development of positive changes in the socialization and behavior of the child after the SCs therapy has been demonstrated, which is proved by the results after ATEC questionnaire assessment. Already over 1 year, we observed significant changes in the psychological and behavioral status of the child. During SCs therapy and within the whole period of follow up for a child, there was no increase of temperature, graft-versus-host reaction or the other undesirable

phenomena. No activation of epileptic activity had been detected; on the contrary, FSCs treatment contributed to improvement of the bioelectrical activity of the brain.

## Conclusion

The case study in a child with ASD presented here demonstrates a high therapeutic effectiveness of FSCs. Initial results showing significant clinical improvements look rather encouraging, but further observation on the stability of all treatment effects and a study on the larger number of ASD patients is needed. The treatment with FSCs administration is a promising and safe method of ASD therapy in children.

## References

1. (U.S. Department of Health and Human Services, National Institutes of Health NIH, Publication No. 25-MH-8084 Revised 2025).
2. Data and Statistics on Autism Spectrum Disorder [https://www.cdc.gov/autism/data-research/index.html?utm\\_source=chatgpt.com](https://www.cdc.gov/autism/data-research/index.html?utm_source=chatgpt.com)
3. Hughes MM, Shaw KA, DiRienzo M et al. Prevalence and characteristics of children with extensive autism, 15 locations, USA, 2000-2016. *Public Health Reports*®. 2023; 138 (6): 971-980. doi: (10.1177/00333549231163551)
4. Guan Joseph and Li Guohua: Injury Mortality in Individuals with Autism. *American Journal of Public Health* 107, 791-793, <https://doi.org/10.2105/AJPH.2017.303696>
5. Roubinov, D., Don, B., Blades, R., & Epel, E. (2023). Is it me or my child? The association between maternal depression and children's behavior problems in mothers and their children with or without autism. *Family Process*, 62, 737–753. <https://doi.org/10.1111/famp.12810>
6. Hodges H, Fealko C, Soares N. Autism spectrum disorder: definition, epidemiology, causes, and clinical evaluation. *Transl Pediatr.* 2020;9 (Suppl 1):S55-S65. doi: 10.21037/tp.2019.09.09.
7. Lukmanji S, Manji SA, Kadhim S, Sauro KM, Wirrell EC, Kwon CS, Jetté N. The co-occurrence of epilepsy and autism: A systematic review. *Epilepsy Behav.* 2019 Sep;98(Pt A):238-248. doi: 10.1016/j.yebeh.2019.07.03
8. Villarreal-Martínez, L., González-Martínez, G., Sáenz-Flores, M. et al. Stem Cell Therapy in the Treatment of Patients with Autism Spectrum Disorder: a Systematic Review and Meta-analysis. *Stem Cell Rev and Rep* 18, 155–164 (2022). <https://link.springer.com/article/10.1007/s12015-021-10257-0>
9. Qu J, Liu Z, Li L, Zou Z, He Z, Zhou L, Luo Y, Zhang M and Ye J (2022) Efficacy and Safety of Stem Cell Therapy in Children with Autism Spectrum Disorders: A Systematic Review and Meta-Analysis. *Front. Pediatr.* 10:897398. doi: 10.3389/fped.2022.897398
10. Jessica M. Sun, Geraldine Dawson, Lauren Franz, Jill Howard, Colleen McLaughlin, Bethany Kistler, Barbara Waters-Pick, Norin Meadows, Jesse Troy, Joanne Kurtzberg, Infusion of human umbilical cord tissue mesenchymal stromal cells in children with autism spectrum disorder, *Stem Cells Translational Medicine*, Volume 9, Issue 10, October 2020, Pages 1137–1146, <https://doi.org/10.1002/sctm.19-0434>
11. Sinelnik, A. A., et al. "Clinical Case of Successful Therapy for the Patient with Autism by use of Fetal Stem Cells." *J Stem Cell Ther Transplant*, 8.1 (2024): 048-053 <https://www.stemcelltherjournal.com/journals/jsctt/jsctt-aid1043.php>.
12. Charitos IA, Ballini A, Cantore S, Boccellino M, Di Domenico M, Borsani E, Nocini R, Di Cosola M, Santacroce L, Bottalico L. Stem Cells: A Historical Review about Biological, Religious, and Ethical Issues. *Stem Cells Int.* 2021 Apr 29; 2021:9978837. doi: 10.1155/2021/9978837. PMID: 34012469; PMCID: PMC8105090.
13. Sivakumar M, Dineshshankar J, Sunil PM, Nirmal RM, Sathiyajeeva J, Saravanan B, Senthilegappan AR. Stem cells: An insight into the therapeutic aspects from medical and dental perspectives. *J Pharm Bioallied Sci.* 2015 Aug;7 (Suppl 2): S361-71. doi: 10.4103/0975-7406.163453. PMID: 26538878; PMCID: PMC4606620.
14. WHO Library Cataloguing-in-Publication Data International statistical classification of diseases and related health problems. - 10th revision, Fifth edition, 2016. 3 v. ISBN 978 92 4 154916 51. (<https://share.google/6i4P3hW8x87iLnNcF>)
15. Geier, D.A.; Kern, J.K.; Geier, M.R. A comparison of the Autism Treatment Evaluation Checklist (ATEC) and the Childhood Autism Rating Scale (CARS) for the quantitative evaluation of autism. *J. Ment. Health Res. Intellect. Disabil.* 6, 255–267 (2013). [Google Scholar] [CrossRef] [PubMed]
16. Peterson T, Sherwin R, Hosey T, et al. (August 13, 2025) Correction: The Effects of Hyperbaric Oxygen Treatment on Verbal Scores in Children with Autism Spectrum Disorder: A Retrospective Trial. *Cureus* 17(8): e248. doi:10.7759/cureus.e248.
17. Xiong T, Chen H, Luo R, Mu D. Hyperbaric oxygen therapy for people with autism spectrum disorder (ASD). *Cochrane Database Syst Rev.* 2016 Oct 13;10(10):CD010922. doi: 10.1002/14651858.CD010922.pub2. PMID: 27737490; PMCID: PMC6464144.
18. Rossignol, D.A., Rossignol, L.W., Smith, S. et al. Hyperbaric treatment for children with autism: a multicenter, randomized, double-blind, controlled trial. *BMC Pediatr* 9, 21 (2009). <https://doi.org/10.1186/1471-2431-9-21>
19. Bradstreet JJ, Sych N, Antonucci N, et al. Efficacy of Fetal Stem Cell Transplantation in Autism Spectrum Disorders: An Open-Labelled Pilot Study. *Cell Transplantation.* 2014;23(1\_suppl):105-112. doi:10.3727/096368914X684916
20. Rosner, M., Horer, S., Feichtinger, M. et al. Multipotent fetal stem cells in reproductive biology research. *Stem Cell Res Ther* 14, 157 (2023). <https://doi.org/10.1186/s13287-023-03379-4>
21. Yamasaki T, Maekawa T, Fujita T, Tobimatsu S. Connectopathy in autism spectrum disorders: a review of evidence from visual evoked potentials and diffusion magnetic resonance imaging. *Front Neurosci.* 2017; 11:627. doi: 10.3389/fnins.2017.00627 [DOI] [PMC free article] [PubMed] [Google Scholar]
22. Billeci, L., Calderoni, S., Tosetti, M. et al. White matter connectivity in children with autism spectrum disorders: a tract-based spatial statistics study. *BMC Neurol* 12, 148 (2012). <https://doi.org/10.1186/1471-2377-12-148>
23. Wolff JJ, Gu H, Gerig G, Ellison JT, Styner M, Gouttard S, Botteron KN, Dager SR, Dawson G, Estes AM, Evans AC, Hazlett HC, Kostopoulos P, McKinstry RC, Paterson SJ, Schultz RT, Zwaigenbaum L, Piven J; IBIS Network. Differences in white matter fiber tract development present from 6 to 24 months in infants with autism. *Am J Psychiatry.* 2012 Jun;169(6):589-600. doi: 10.1176/appi.ajp.2011.11091447. PMID: 22362397; PMCID: PMC3377782.
24. Qing, P., Zhang, X., Liu, Q. et al. Structure-function coupling in white matter uncovers the hypoconnectivity in autism spectrum disorder. *Molecular Autism* 15, 43 (2024). <https://doi.org/10.1186/s13229-024-00620-6>



This work is licensed under Creative Commons Attribution 4.0 License

To Submit Your Article Click Here: [Submit Manuscript](#)

DOI:10.31579/2690-1919/568

**Ready to submit your research? Choose Auctores and benefit from:**

- fast; convenient online submission
- rigorous peer review by experienced research in your field
- rapid publication on acceptance
- authors retain copyrights
- unique DOI for all articles
- immediate; unrestricted online access

At Auctores; research is always in progress.

Learn more <https://www.auctoresonline.org/journals/journal-of-clinical-research-and-reports>